

2014

Shoulder Impingement in Water Polo Players

Kelly A. Davis
Scripps College

Recommended Citation

Davis, Kelly A., "Shoulder Impingement in Water Polo Players" (2014). *Scripps Senior Theses*. Paper 324.
http://scholarship.claremont.edu/scripps_theses/324

This Open Access Senior Thesis is brought to you for free and open access by the Scripps Student Scholarship at Scholarship @ Claremont. It has been accepted for inclusion in Scripps Senior Theses by an authorized administrator of Scholarship @ Claremont. For more information, please contact scholarship@cuc.claremont.edu.

Shoulder Impingement Syndrome in Water Polo Players

A Thesis Presented

By

Kelly Davis

To the Keck Science Department

Of the Claremont Colleges

In Partial Fulfillment of the Degree of Bachelor of Arts

Steve Graves ATC

Dr. John Milton

Senior Thesis in Organismal Biology

December 9, 2013

Scripps College

Table of Contents

Abstract:	3
Introduction:	3
Anatomy:	8
Bony Elements:	8
Ligaments and Joints:	12
Muscle:	16
Bursae:	21
Kinematics	23
Freestyle Swimming Shoulder Kinematics	25
Shoulder Impingement	27
Description:	27
Diagnostics:	30
Effects of Impingement on Head-Down Swimming:	34
Mechanisms of Impingement Development in Head-Down Freestyle	36
Head-Up Freestyle Kinematics	38
Research Proposal	39
Title:	39
Significance of Proposed Research:	39
Methods:	40
Participants:	40
Materials and Data Collection:	41
Statistical Analysis:	43
Confounding Variables:	43
Conclusions:	44
Appendix: IRB Materials	47
Acknowledgements	56
Works Cited	57

Abstract:

Water polo is a physically demanding sport that has not inspired much research. Water polo puts its players at high risks for shoulder injuries since the motions required to perform the sport at an optimum level push the limits of normal shoulder function.

Shoulder impingement is common among water polo players. Impingement is a pathologic limitation of subacromial space that causes structures to be in abnormal contact with each other, causing abrasive and pinching forces which can cause maladies including bursitis, tendinitis, and tearing of muscles and ligaments.

Freestyle swimming used in water polo is a stroke known as head-up freestyle, rather than the traditional well researched head-down freestyle. Hitherto unknown are the biomechanics and the extent to which impingement in is caused and/or worsened by this form of freestyle.

The proposed research is a two-part study to investigate the biomechanics of head-up freestyle. Experienced water polo players' head-up freestyle kinematic sequences and muscle activities will be recorded by high-speed cinematography and fine-wire electromyography. These data will be used to help understand the biomechanical differences between head-up in and head-down.

Part II of the study will recruit experienced water polo players with existing shoulder impingement. Their head-up freestyle will be recorded in the same manner. These data will be compared to those in Part I to understand how the head-up stroke differs between impinged and healthy shoulders. This research will provide a basis for the understanding of impingement in head-up freestyle to ultimately increase the safety of the players.

Introduction

Owing to its highly mobile nature, the shoulder is often susceptible to injury. It has the highest range of mobility of any joint in the body, with up to 180 degrees of circumduction. In contrast, the next most flexible joint is the hip, with up to 130 degrees of flexion and up to 50 degrees of abduction (Kurz, 2003). As a general rule with joints, there is an inverse relationship between flexibility and stability; the ability of muscles, tendons, and ligaments to hold the bones in place is greatly diminished with increased degrees of rotation since the dynamic stability provided by the soft tissue structures are subject to a large amount of variability. In contrast, joints with smaller degrees of

rotation are optimized for stability rather than motion, and these joints are therefore relatively less susceptible to injury, such as the sternoclavicular joint.

Several types of musculoskeletal shoulder injuries are possible, each with varying degrees of severity. These include acute injuries and traumas such as bone breaks, tendon and ligament ruptures, and muscle tears, as well as chronic injuries such as tendinitis, osteoporosis, and impingement. Such injuries have been reported with increasing frequency in recent years, largely due to competitive sports. Athletics have significantly contributed to these increases as results of overuse, improper technique and impact injuries. Overhead sports (those that require frequent abduction of the shoulder to or above 90 degrees), in particular, represent a large percentage of such injuries. Even sports like swimming, which have lower risks for impact injuries, have been yielding increasingly high instances of joint injuries due to the increase in competitiveness and amounts of training. Impingement represents one such major group of injuries in overhead athletes.

The colloquial idea of swimming as a “perfect” sport has been perpetuated for many years since it boasts virtually no external impact on joints, but this idea is quickly becoming outdated. Though it is true that the act of swimming for exercise has significantly less impact than terrestrial exercise, competitive swimmers swim such great distances with such intensity that the repeated closed-chain kinematics can cause significant wear and tear injury to joints. Experts estimate that year-round competitive swimmers cover between 10,000 to 24,000m per day (Browne, Pink, Jobe, & Kerrigan, 1988; Heinlein & Cosgarea, 2010). Over half of competitive swimmers over age 12

suffer from shoulder pain, and the incidence of shoulder pain among swimmers can reach up to 80% (Levy & Fuerst, 1993; Franić, Ivković, & Rudić, 2007).

Water polo players also regularly swim great distances and are also frequently affected by shoulder pain. Colville and Markman estimate that the frequency of shoulder injuries among elite water polo players is around 80% (1999). In contrast to swimming, however, there are many additional potential causes of such pain including passing, shooting, sculling (a sweeping motion with the arm in the horizontal plane to aid the player in staying afloat), and impact with the ball or other players. The dynamic quality of the sport contributes to the high incidence of shoulder injuries since there are ample opportunities for initial injury, as well as opportunities for further injuries from other aspects of the sport. It is well known in the literature that both throwing sports and swimming are at high risk for shoulder injuries, so it is no surprise that water polo athletes incur similar injuries; it is not known, however, the interaction between the throwing and swimming aspects of the sport.

The kinematics involved in water polo are similar to those in other sports, yet there are vital differences that could potentially alter their musculoskeletal effects completely. For example, throwing in water polo uses a similar kinematic sequence as is seen in baseball, but it is inherently different in that the ground cannot be used for a solid base of support. Furthermore, the style of freestyle swimming in water polo differs from that of competitive swimming in that the head and chest are brought up out of the water with shorter strokes, known as head-up freestyle. Before the interaction between these two motions can be sufficiently analyzed and understood, it is essential to first understand each motion's biomechanics separately as well as the ways in which each

motion can cause injury. Since it is possible that water polo's head-up freestyle could potentially either significantly increase or decrease the risks of shoulder injury, it begs the question: how does lifting the head and chest alter the kinematics and biomechanics of freestyle swimming in head-up water polo and how does this alter the risk of injury? This is the question that serves as the motivation for the proposed research.

The research proposed will be conducted in two parts and will recruit experienced water polo players both with and without impingement. In Part I, the kinematic sequence and muscle activation of the head-up freestyle with healthy shoulders will be determined and compared to that of normal head-down freestyle as established in the literature. Part II will study the differences between head-up freestyle kinematics and muscle activation in subjects with prior shoulder impingement syndrome and in subjects with healthy shoulders. Data for both parts will be gathered with high-speed cameras and electrodes while the subjects perform head-up freestyle swimming. These data will give insight into potential sources and aggravation of impingement in these athletes and ultimately aid in increasing the safety of water polo athletes. Following this study, it would be important to investigate this topic further by comparing the patterns of alterations in swim strokes as shoulders go from healthy to impinged between head-up and head-down swimming, to analyze instances of impingement in each phase of the stroke cycle in head-up freestyle, and to determine how biomechanics and rates of impingement are altered in fatigued swimmers or swimmers with suboptimal form.

Anatomy

The shoulder's anatomy is complicated in that it is not one singular joint but rather a highly mobile complex. It is comprised of three bones, three separate joints, 18 total ligaments and cartilages, four bursae, and involves no less than 17 muscles (Gray, 1977).

Bony Elements:

The shoulder unit is comprised of three major bones: the humerus, the scapula, and the clavicle, pictured in Figure 1.



*Figure 1: The bony elements of the shoulder are the humerus, scapula, and clavicle. Each bone has several integral features that contribute to the function of the shoulder.
(Image from <http://yourchiroclinic.co.uk/special-offers/shoulder-anatomyfunction-impingement>)*

Clavicle:

The clavicle, or collarbone, is an elongated S-shaped bone that lies superior to the rib cage, pictured in Figure 2. This curvature allows for some elasticity to cope with the strong muscular forces and external forces to which it is often subjected (Gray,

1977). At its medial end, it articulates with the sternum at the clavicular notch of the manubrium, forming the sternoclavicular joint, as well as with the cartilage of the first rib. Distally, it articulates with the acromion process of the scapula, forming the acromioclavicular joint. Though it is a crucial element of the shoulder, it is a multifunctional element in that it also attaches to muscles that have no direct relation to shoulder function. This bone is particularly important because it serves as the only connection between the axial skeleton and the arm and because it acts as a fulcrum to allow lateral motion of the upper extremity (Gray, 1977).



Figure 2: The clavicle is a curved bone that articulates with the acromion at the acromial extremity and the sternum at the sternal extremity.

(Image from <http://conornordengren.com/tag/thoracic-mobility/>)

Scapula:

The scapula, pictured in Figure 3, is a roughly triangular- or spade-shaped bone that sits superior and posterior to the rib cage overlaying ribs 2-7 and sometimes 8, and tilted anteriorly 30 degrees (Gray, 1977; Tagliafico, 2012). The largely concave anterior face is called the subscapular fossa, which provides a large surface area for muscle attachment (Gray, 1977). The posterior face of the scapula is subdivided into two sections, the supraspinous fossa and the infraspinous fossa. The supraspinous fossa is concave while the infraspinous fossa is shallowly concave at its superior portion and


convex at its center (Gray, 1977). These two sections are separated by a prominent ridge called the scapular spine, which runs obliquely from the upper third of the medial border to the superior edge of the lateral border where it extends to become the acromion process (Gray, 1977; Tagliafico, 2012). The upper face of the acromion convex and articulates with the lateral end of the clavicle while also providing muscle and ligament attachment points (Gray, 1977; Tagliafico, 2012). The under surface is concave and is the origin of several integral shoulder muscles (Gray, 1977). Another crucial scapular element is a small, thick, curved process that protrudes off the anterior lateral superior corner, called the coracoid processes, which also provides for muscle and ligament attachment (Gray, 1977; Tagliafico, 2012). Lastly, the glenoid fossa is a small shallow concave curvature on the lateral superior border of the scapula known as the head (Gray, 1977; Tagliafico, 2012). It lies inferior to both the coracoid process and the acromion, and is ventral to the acromion and posterior to the coracoid, and articulates with the humeral head (Gray, 1977).



*Figure 3: The scapula is a complex bone with several key features that contribute to the function of the shoulder.
(Image from: <http://thesebonesofmine.wordpress.com/category/scapula/>)*

Humerus:

The humerus, or upper arm bone, is a large elongated bone that articulates with the glenoid fossa at its proximal end and extends to articulate with the radius and ulna at its distal end, pictured in Figure 4. The functional components of the humerus in relation to the shoulder are the humeral head, the greater and lesser tubercles, and the intertubercular groove. The humeral head is nearly hemispherical and is the element that articulates with the glenoid fossa. Distal to the head is the anatomical neck, the tubercles, the surgical neck, and the shaft (Gray, 1977). The anatomical neck is the border between the head and the rest of the bone while the surgical neck is just beyond the tuberosities where the shaft of the humerus starts (Gray, 1977). The surgical neck is named as such because it is the point at which breaks are most common (Gray, 1977; Tagliafico, 2012). Between these two necks are two tubercles; the greater tubercle is on the lateral edge of the humerus and is rounded with three facets, and the lesser tubercle is on the ventral edge and directed inward and forward with one facet. Between these tubercles runs the bicipital (intertubercular) groove, which allows for tendon attachment of the long head of the biceps brachii.



*Figure 4: The critical features of the humerus in relation to the shoulder are the greater and lesser tubercles, the bicipital groove, and the head.
(Image from: <http://iowa.247sports.com/ImageUrl/914427?View=Detailed>)*

Ligaments and Joints:

Between these three bones, there are two main joints: the glenohumeral and the acromioclavicular joint. In addition, the articulation of the clavicle with the sternum (sternoclavicular or SC joint) plays an indirect role, and the ligamentous connection between the acromion and coracoid processes (coracoacromial ligament) is structurally important. These structures are pictured in Figure 5.

The major functional unit of the shoulder complex is the glenohumeral (GH) joint, which is the articulation of the humeral head within the glenoid fossa. This synovial joint is classified as a ball-and-socket joint since the rounded humeral head sits in the hyaline cartilage of the concave glenoid fossa much like a golf ball in a tee (Tagliafico, 2012; Van De Graaff, 2002). As opposed to all other types of joints, ball and socket joints such as the shoulder are triaxial since they can move in three planes, the sagittal, frontal, and horizontal (Behnke, 2006). In the sagittal plane, the upper

extremity can rotate about a frontal horizontal axis by flexing and extending (Behnke, 2006). By adducting and abducting about a sagittal horizontal axis, it can move in the frontal plane (Behnke, 2006). Finally, it can move about a vertical axis in the horizontal plane by internally and externally rotating (Behnke, 2006).

The high degree of mobility of this joint is made possible in part by the size differential between the diameters of the humeral head and the glenoid fossa, respectively; the humeral head is much larger in diameter than is the shallowly concave glenoid fossa, minimizing direct contact and maximizing rotation. With so little direct contact, there is a lack of stability. This is mediated in part by the action of the glenoid labrum, which essentially acts to deepens the concavity of the glenoid fossa, creating more stability while still maintaining flexibility (Tagliafico, 2012; Van De Graaff, 2002). In addition, the superior, middle, and inferior glenohumeral ligaments provide further support. The superior glenohumeral ligament spans the rotator interval area, which is the space between the supraspinatus tendon and the subscapularis tendon, and acts to support the long head of the biceps tendon (Tagliafico, 2012). Secondly, the middle GH ligament can either originate with the superior GH ligament alone or with the inferior GH ligament as well (Tagliafico, 2012). It inserts at the base of the lesser humeral tubercle before which it blends with the supscapularis tendon, and its main action is the support of several variants (Tagliafico, 2012). Lastly, the inferior GH ligament is a complex of three bands. The anterior band inserts on the anterior glenoid rim at the mid-glenoid notch, and the posterior band attaches to the posterior inferior glenoid quadrant (Tagliafico, 2012). The last band, which attaches to the humerus, can have two types of attachment: collar-like, in which the entire inferior GH ligament inserts slightly

inferior to the articular edge of the humeral head, and V-shaped attachment, in which the anterior posterior bands of the inferior GH ligament attach adjacent to the articular edge of the humeral head, and the axillary pouch attaches to the apex of the V distal to the articular edge (Tagliafico, 2012). Lastly, a thin band that runs from the greater tubercle to the lesser tubercle called the transverse humeral retinaculum provides an extra degree of stability for the structures that insert and originate on the humeral head (Van De Graaff, 2002). These GH ligaments work in conjunction to provide stability to the glenohumeral joint without compromising mobility.

Beyond the GH joint itself, the acromioclavicular (AC) joint is critically important because it is the only element that transfers forces between the upper arm and shoulder to the axial skeleton (Gray, 1977; Tagliafico, 2012). It occurs at between the distal end of the clavicle and the medial aspect of the anterior acromion. This joint has a much greater degree of structural integrity than the GH joint since it is a cartilaginous joint, and it has minimal mobility (Tagliafico, 2012). The mobility that it does retain is a gliding motion between the articular end of the clavicle and the acromion, and a rotation of the scapula relative to the clavicle. Three soft tissue elements work in conjunction with the bony clavicle and acromion to create this joint. The first is the meniscoid disc, which is a fibrocartilaginous structure in the joint space that acts as a bumper to absorb impact and lessen friction. Secondly, the acromioclavicular (AC) ligament provides a connection between the clavicle and the acromion. This ligament has strong superior and inferior elements while having weak anterior and posterior elements, creating an overall restriction of anterior-posterior movements of the clavicle (Tagliafico, 2012). The coracoclavicular (CC) ligament also plays an important role in

the AC joint by way of its two fasciculi, conoid and trapezius, that create a strong, heavy band. This ligament largely restricts vertical movements of the clavicle (Gray, 1977; Tagliafico, 2012).

Though not technically joints, the scapula also contains two ligaments within itself. The first is the coraco-acromial ligament, which, as its name suggests, connects the coracoid process with the acromion. It runs over the supraspinatus tendon and a bursa and under the deltoid and clavicle, and it serves to protect the humeral head. Additionally, the transverse ligament (also called the coracoid or suprascapular ligament) runs laterally over the suprascapular notch, functionally making the notch a foramen through which runs the suprascapular nerve and over which runs the suprascapular vessels (Gray, 1977).



Figure 5: Ligaments of the shoulder are complex and help to provide stability. (Image from: <http://www.blog.sportstrap.com.au/how-to-strap-a-shoulder/>)

Lastly, the articulation between the medial end of the clavicle and the upper lateral parts of the manubrium of the sternum is called the sternoclavicular joint. The ligaments and cartilages involved in this articulation are the capsular ligament, which completely envelops the joint; the anterior sterno-clavicular ligament, which spans the anterior superior portion of the medial end of the clavicle to the anterior superior portion of the manubrium, running obliquely posterior; the posterior sterno-clavicular ligament, which roughly mirrors the anterior sterno-clavicular on the posterior aspects of the same elements; the interclavicular ligament, which connects the anterior medial aspects of both clavicles and attaches to the anterior edge of the manubrium in between; the costo-clavicular ligament, which attaches the superior interior portion of the first rib to the rhomboid depression on the posterior surface of the clavicle; and the interarticular fibro-cartilage, which is a disk that occurs between the articular surfaces of the clavicle and manubrium. This joint is especially important in throwing motions because it is able to transfer forces between the axial skeleton and the appendicular skeleton, and it is essentially the origin of all shoulder movement (Behnke, 2006; Gray, 1977).

Muscle:

The shoulder uses a variety of muscles to perform its full range of nuanced motions. The scapula alone attaches to seventeen muscles (Gray, 1977; Tagliafico, 2012). The deepest four muscles, the suprapinatus, infraspinatus, subscapularis, and teres minor make up what is colloquially known as the rotator cuff (Figure 6).

The subscapularis lies between the anterior surface of the scapula and the posterior surface of the thorax. It originates along the anterior medial edge of the subscapular fossa and has multiple insertion points: it has broad insertion on the lesser tuberosity of the humerus and its cranial fibers insert on the greater tuberosity. This muscle functions to adduct and internally rotate the humerus (Behnke, 2006; Gray, 1977; Tagliafico, 2012).

The infraspinatus muscle roughly mirrors the subscapularis on the posterior surface of the scapula. It originates along the posterior medial border of the scapula in the infraspinous fossa and inserts on the middle facet of the greater tuberosity of the humerus, functioning as an external rotator of the humerus (Behnke, 2006; Tagliafico, 2012). Its action is an external rotator and extensor of the shoulder joint (Behnke, 2006).

The supraspinatus muscle runs along the superior border of the scapula and under the coracoacromial arch, which is formed by the ligamentous connection between the coracoid process and the acromion. The supraspinatus originates superior to the infraspinatus along the superior third of the posterior medial border of the scapula and inserts on the greater tuberosity of the humerus (Tagliafico, 2012). It is somewhat of an antagonistic muscle to the subscapularis in that it abducts rather than adducts, but it is agonistic in that it also internally rotates the humerus.

The last of the rotator cuff muscles is the teres minor. Originating along the inferior third of the lateral border of the scapula in the infraspinatus fossa, it runs laterally to insert on the distal facet of the greater tuberosity of the humerus (Tagliafico,

2012). As an agonistic muscle to the supraspinatus, it also functions as an external rotator and extensor (Behnke, 2006; Tagliafico, 2012)

These four rotator cuff muscles are integral to the function of the shoulder as they are the main stabilizers of the glenohumeral joint, the essential motor unit of the shoulder. Without these muscles, the ligaments and joint capsules holding the bony elements in place would not generate enough force to keep the humeral head in contact with the glenoid fossa in static positions. Additionally, during overhead motions, these muscles provide stabilizing force during acceleration phases as well as during deceleration phases when their eccentric contractions apply braking forces (Kibler, 1998).



Figure 6: The four muscles that make up the rotator cuff provide stability as well as a small degree of mobility to the shoulder complex.

(Image from: <http://www.nlm.nih.gov/medlineplus/ency/imagepages/19622.htm>)

Several other muscles outside the rotator cuff muscles are critically important in the function of the shoulder. The trapezius, latissimus dorsi, levator scapulae, rhomboid major and minor, pectoralis major, pectoralis minor, deltoid and serratus anterior

constitute the intrinsic muscles (Tagliafico, 2012). The extrinsic muscles of the shoulder complex include the teres major, coracobrachialis, biceps brachii and subclavius, as depicted in Figure 7 (Tagliafico, 2012).

The trapezius muscle is a wide-spanning muscle with a multitude of functions, both related and unrelated to the shoulder. It originates from the spinous processes of vertebra C7-T12 as well as the external occipital protuberance, and it inserts on the lateral third of the clavicle, scapular spine, and the acromion (Tagliafico, 2012). It acts as to elevate and rotate the scapula (Tagliafico, 2012).

The latissimus dorsi muscle is another large muscle with several functions. It originates inferior to the trapezius, from the lumbosacral fascia of vertebrae T7-T12, the 10th, 11th, and 12th ribs, and the iliac crest (Tagliafico, 2012). It inserts on the basal bicipital groove between the greater and lesser tuberosities of the humerus and acts as an extensor, internal rotator, and humeral adductor (Tagliafico, 2012).

The levator scapulae originates superior to the trapezius and latissimus dorsi on the transverse processes of vertebrae C1-C4 and inserts on the medial angle and root of the scapula (Tagliafico, 2012). It acts to elevate the scapula as well as rotate the scapula agonistically with the serratus anterior.

The rhomboid major originates on the spinous processes of vertebrae T5-T7 and inserts on the medial border of the scapular spine whereas the rhomboid minor originates from the spinous processes of vertebrae C7-T1 and insert on the scapular spine. Both muscles work agonistically to retract and elevate the scapula.

The pectoralis major originates along the sternal half of the clavicle, the sternum, the 7th rib, and the aponeurosis obliquum externum and inserts on the lateral lip of the

bicipital groove of the humerus (Tagliafico, 2012). This muscle acts to adduct and internally rotate the humerus (Tagliafico, 2012).

The pectoralis minor serves to stabilize the scapula. It originates along the 3rd-5th ribs and inserts on the coracoid process of the scapula (Tagliafico, 2012).

The deltoid owes its name to the Greek letter Delta because of its triangular shape. It originates along the anterior border and the upper surface of the lateral third of the clavicle, the acromion, and the scapular spine and inserts on the deltoid tuberosity of the humerus, which is distal to the surgical neck on the lateral shaft (Tagliafico, 2012). It acts to abduct, flex, extend, and externally rotate the humerus (Tagliafico, 2012).

The final intrinsic muscle is the serratus anterior muscle, which originates from the anterior surface of the 1st through 9th rib and inserts on the anteromedial border of the scapula. The function of this muscle is stabilization of the scapula.

Extrinsically, the teres major originates on the inferior posterior angle of the scapula and inserts along the medial lip of the bicipital groove. This muscle acts to extend, internally rotate and adduct the humerus (Tagliafico, 2012) .

The coracobrachialis originates on the coracoid process and inserts on the medial third of the humerus, hence its name. It works to flex and supinate the forearm (Tagliafico, 2012).

The biceps brachii is an integral muscle to the arm and shoulder system. The long head originates from the superior glenoid tubercle while the short head originates on the coracoid process. Insertion occurs on the radial tuberosity of the forearm, which

allows this muscle to flex and supinate the arm, similar to the function of the coracobrachialis (Tagliafico, 2012).

Finally, although not integrally important to the movement of the shoulder, the subclavius muscle is important because it acts as a depressor of the clavicle. It originates from the 1st rib and costal cartilage and inserts along the inferior border of the clavicle (Tagliafico, 2012).




*Figure 7: The superficial muscles of the shoulder a) anterior and b) posterior.
(Images from: http://www.physioweb.org/muscular/muscle_names.html)*

Bursae:

In addition to the bones, muscles, cartilages, tendons, and ligaments, the shoulder also contains four bursae, which are essentially thin pouches of synovial fluid formed from extensions of the synovial membrane that function to reduce friction between muscles, ligaments, and bones during movement (Tagliafico, 2012; Van De Graaff, 2002). These four bursae, pictured in Figure 8, are classified as two major and two minor bursae: the sub-acromial, and the subdeltoid are the major bursae while the subcoracoid and the subscapular bursae are the minor (Tagliafico, 2012; Van De Graaff,

2002). As their names suggest, the sub-acromial is inferior to the acromion and superior the GH joint capsule, the subdeltoid is inferior to the deltoid and superior to the joint capsule, the subcoracoid is inferior to the coracoid and superior to the joint capsule, and the subscapular is interior to the tendon of the subscapularis muscle and superior to the joint capsule. Each bursa is important, but the subcoracoid and sub-acromial are arguably the most important since they tend to incur major injuries. The subcoracoid bursa's role is minimizes friction between the subscapularis tendon, biceps short head tendon, and the coracobrachialis tendon when the humeral head rotates, so it is often subject to a great deal of stress when biomechanical abnormalities occur (Tagliafico, 2012). Similarly, the sub-acromial bursa reduces friction between the acromion and the tendon of the supraspinatus muscle (Tagliafico, 2012).



*Figure 8: Bursae of the shoulder
(Image from: <http://www.mendmeshop.com/bursa/shoulder-bursitis.php>)*

Kinematics

As aforementioned, the movement of the shoulder is complicated and nuanced due to the intricacy of its components and its large degree of flexibility. The key factor in this flexible condition is the size ratio of the humeral head to the glenoid fossa; the glenoid is fairly small and shallowly concave compared to other ball and socket joints such as that of the hip, decreasing the amount of contact and thereby allowing the humeral head a much greater range of rotation. Adding to the glenoid-humeral movement itself, the glenoid can change angles due to the action of the rotator cuff muscles on the shoulder girdle to alter the scapula's position in relation to the thorax (Behnke, 2006).

Being such a mobile component of the shoulder, the scapula is vitally important in kinematics. As explained by Kibler, the scapula has five major roles during overhead throwing and serving actions including stability for GH articulation, retraction and protraction along the thoracic wall, elevation of the acromion, a base for muscular attachment, and the link in proximal-to-distal sequencing of velocity, energy, and forces (1998).

From anatomical resting position, a normally functioning shoulder complex can abduct, adduct, flex, extend, protract, retract, circumduct, and medially and laterally rotate internally and externally (Meister, 2000). These basic motions, pictured in Figure 9, can be combined to varying degrees to create the aforementioned wide range of flexibility of up to 180 degrees of motion.



*Figure 9: Normal range of motion (ROM) of the human shoulder in forward extension/flexion, abduction/adduction, internal/external rotation, and horizontal flexion/extension.
(Image from: <http://corawen.com/2011/07/27/the-rom-of-major-joints/>)*

Freestyle Swimming Shoulder Kinematics


Swimming kinematics are inherently complicated since swimming is not a natural movement for the human body, and it takes years of training to achieve expertise. Shoulders are integral to the kinematic sequence since up to 90% of the forward propulsive power is produced by the arms, according to Pink and Tibone's 2003 study (cited in Heinlein & Cosgarea, 2010).

The arm stroke utilizes the full range of shoulder motion, and can be divided into three major steps: glide/reach, pull-through, and recovery, pictured in Figure 10. The glide phase begins as the hand enters the water in front of the head and the arm straightens out to full abduction and extension of the arm. During this phase, the scapula is stabilized by the action of the rhomboids anchoring the superior angle of the scapula while the upper trapezius and serratus anterior achieve upward rotation (Heinlein & Cosgarea, 2010).

Next, the pull-through phase can be further subdivided into three stages. Early pull-through begins at maximum arm extension and ends when the humerus is perpendicular to the trunk of the body. It utilizes the pectoralis major and teres minor to extend, adduct, and internally rotate the humerus and this moving the arm in a downward arc (Heinlein & Cosgarea, 2010). Mid-pull-through occurs between early and late pull-through as a transition step and activates the serratus anterior, pectoralis major, and latissimus dorsi (Heinlein & Cosgarea, 2010). Finally, from the point at which the arm is extended 90 degrees until the hand exits the water constitutes the late

pull-through phase and is characterized by latissimus dorsi and subscapularis activation (Heinlein & Cosgarea, 2010).

The transition to the recovery phase starts as the hand exits the water. At this point, the arm is not contributing to any forward motion until it begins the glide phase again. The posterior deltoid, middle deltoid, and supraspinatus are at work during this phase while the rhomboids retract the scapula. The rhomboid action also starts the lateral body roll needed for the opposite arm to actively pull through the water (Heinlein & Cosgarea, 2010). At the end of this phase, the posterior deltoid extends the arm, the middle deltoid abducts, and the anterior deltoid flexes the shoulder (Heinlein & Cosgarea, 2010).




*Figure 10: Muscle activity during each phase of the swim stroke.
(Image from: Heinlein & Cosgarea, 2010, adapted with permission from Colwin CM. Breakthrough Swimming.
Champaign, IL: Human Kinetics; 2002:50-70)*

Shoulder Impingement

Description:

Injuries caused by shoulder impingement are fairly common and potentially debilitating, and they can occur among all overhead athletes including baseball players, football players, swimmers, handball players, kayakers, water polo players, and many more. These athletes are particularly at risk since they are constantly performing motions at the limits of the range of shoulder motion under extreme conditions (Drakos, Rudzki, Allen, Potter, & Altchek, 2009). In addition, impingement itself can cause a range of specific group of musculoskeletal shoulder abnormalities in which structures are pinched due to lack of space, its symptoms overlap with other shoulder maladies, and it is responsive to a multitude of treatment options. These factors combined with the inherently complex structure of the shoulder make impingement an important and complicated occurrence to study.

Shoulder impingement syndrome is an umbrella term to describe several pathologic conditions in which an abnormal space limitation causes a pinching of structures of and surrounding the glenohumeral joint in the subacromial space, pictured in Figure 11. These conditions include articular-sided rotator cuff tears, labral tears, biceps tendinitis, anterior instability, internal rotation deficit, scapular dysfunction (Drakos et al., 2009). "Impingement," therefore, refers to the mechanism of injury rather than the physical tearing of muscles and tendons that it causes.



*Figure 11: The subacromial space is the area beneath the acromion and coracoacromial ligament.
(Image from: <http://morphopedics.wikidot.com/shoulder-joint-impingement-type-syndromes>)*

Shoulder impingement occurs at three stages of severity as described by Neer. The first stage of severity is edema and hemorrhage within the shoulder, and is typically seen in overhead athletes under 25 years of age (Neer, 1983). This stage is fairly easily reversed with proper stretching and strengthening exercises, which must be tailored to the affected individual's particular shoulder malady. The second stage is fibrosis and tendinitis, which typically presents among individuals between 25 and 40 years of age and may require a higher level of treatment including bursectomy or coracoacromial ligament division if conservative treatment fails repeatedly (Neer, 1983). In this stage, the bursae become fibrotic due to repeated mechanical inflammation. Finally, stage three almost exclusively occurs among individuals aged 40 years or older and includes rotator cuff tears, biceps ruptures, and bone changes at the anterior acromion and greater tuberosity (Neer, 1983).

Two major distinctions, structural and functional, refer to the pathogenesis of the syndrome. Structural impingement, also referred to as primary, is indicative of an

anatomical abnormality that causes the pathologic decrease of subacromial space. Most often, this type of impingement is due to a hooked acromion as opposed to the asymptomatic rounded shape, which causes the long head of the biceps brachii to be pressed against the acromion during shoulder movement (figure 12).



Figure 12: Acromion types-- type 1, normal acromion; Type 2, rounded/curved acromion; Type 3, hooked acromion. (Image from: <http://www.shoulderdoc.co.uk/articletile.asp?article=48§ion=9&tile=2>)

In addition, structural impingement can be caused by a shallow or laterally placed bicipital groove, also causing abrasion to the long head of the biceps tendon (Neer, 1983). Alternatively, functional impingement, or secondary impingement, is caused by inabilities of the musculature to keep the humeral head in place within the glenoid fossa. When this occurs, the humeral head is translated abnormally, especially during movements, causing compression between the soft and bony tissues (Franić et al., 2007; Saulsbery & Hollister, n.d.).


Impingement presents in four major patterns: subacromial impingement, coracoacromial impingement, subcoracoid. Subacromial impingement occurs when the rotator cuff is compressed by the acromion process (Saulsbery & Hollister, n.d.; Witwer & Sauers, 2006). In coracoacromial impingement, structures are impinged on the coracoacromial arch. Subcoracoid impingement, also known as stenosis, refers to

anterior shoulder pain caused by rotator cuff musculature being impinged on the coracoid process (Saulsbery & Hollister, n.d.). Lastly, internal or glenoid impingement refers to pain in the posterior portion of the shoulder, especially during overhead motions in athletes (Saulsbery & Hollister, n.d.).

Diagnostics:

Given the complicated definition of impingement, it is a difficult condition to diagnose. Several methods are often used, including manipulative tests and imaging techniques. Manipulative tests are the easiest, cheapest, and most non-invasive, but they are limited in that they cannot distinguish the stage of injury.

One such manipulative test developed by Neer is aptly named the Neer Impingement Sign, or the passive painful arc maneuver, pictured in Figure 13 (Saulsbery & Hollister, n.d.). In this test, the greater tuberosity is forced against the anterior acromion by preventing scapular motion and forcing forward elevation (Neer, 1983; Saulsbery & Hollister, n.d.). The examiner performs this test by forcibly moving the patient's pronated hand in forward elevation while keeping a hand on the patient's scapula to 180 degrees overhead (Neer, 1983; Saulsbery & Hollister, n.d.). Pain during this maneuver indicates not just impingement, but a variety of shoulder issues. A positive impingement test distinguishes impingement from these other issues with an injection of 10 cc of 1.0% xylocaine beneath the acromion. If pain is significantly reduced, the test is positive for impingement (Neer, 1983).



*Figure 13: Neer's impingement sign
(Image from: <http://www.aafp.org/afp/2005/0901/p811.html>)*

Another manipulative test, called the Jobe relocation test, is performed with the patient supine with the arm abducted 90-100 degrees with maximal external rotation (Figure 14). This test is positive if pain is reproduced when the arm is pulled anteriorly but alleviated when a posterior force is directed at the humeral head (Drakos et al., 2009).



Figure 14: Jobe's relocation test. A. Abduction and maximum external rotation causes pain in impinged shoulders B. Posteriorly directed force on the humeral head reduces pain in impinged shoulders (Meister, 2000)

The Hawkins impingement sign tests for the presence of impingement by forcing the tendons of the rotator cuff muscles against the coracoacromial arch. The patient's arm is flexed forward to 90, as is the elbow. The examiner then externally and internally rotates the shoulder by manipulating the patient's hand and wrist. The presence of pain

with external rotation indicates impingement of the subscapularis muscle against the coracoacromial arch whereas pain with internal rotation indicates impingement of the supraspinatus, teres minor, and infraspinatus muscle tendons (Saulsbery & Hollister, n.d.).



Figure 15: Hawkins impingement sign
(Image from: http://www.medscape.org/viewarticle/529345_2)

Lastly, the supraspinatus test identifies rotator cuff weakness by failure to resist the examiner's pressure on the patient's arms. The patient holds the affected arm abducted 90 degrees and adducted 30 degrees first with the hand pronated and thumb facing downward while the examiner applies downward pressure on the arm (Figure 16). Muscle weakness indicates impingement of the supraspinatus tendon (Saulsbery & Hollister, n.d.). This test can also be done with the hand supinated and thumb facing upward so as to not illicit as much pain in the patient.



*Figure 16: The supraspinatus test is also called the "empty can" test.
(Image from: <http://www.aafp.org/afp/2000/0515/p3079.html>)*

Diagnostic imaging techniques useful for impingement includes radiography, MRI, and arthroscopy. Radiographs are particularly useful for identifying the Bennett lesion, an ossification on the posteroinferior aspect of the glenoid rim, and increased sclerosis at the base of the greater tuberosity (Drakos et al., 2009).

MRI is especially useful in diagnosing shoulder conditions since its accuracy can reach up to 95% for labral tears and rotator cuff maladies (Drakos et al., 2009). In addition, MRI can utilize several alterations to visualize the small labral tears easier, including gadolinium-enhanced and non-contrast MRI. Labral tears, rotator cuff disease, undersurface tears of the supraspinatus and infraspinatus tendons, cystic changes in the posterior aspect of the humeral head, as well as asymptomatic conditions (Drakos et al., 2009).

Computed tomography, though not commonly used, can be used to identify internal impingement as well. Humeral and glenoid abnormalities are especially well visualized with this method with the benefit of three-dimensional imaging. Arthroscopy can also be used to identify impingement, but as it is an invasive procedure, it is not used unless the above methods have failed.

Effects of Impingement on Head-Down Swimming:

As aforementioned, shoulder impingement syndrome is not uncommon among swimmers and water polo players. Typically, these athletes develop impingement with overuse and bad form. Overuse tends to wear down tendons, muscles, and articular cartilage, especially in individuals with hooked acromions. In addition, overworking the rotator cuff muscles can cause microtears that lead to shoulder imbalances. Bad form can also cause injury as it can create excess stress on the structures that are already being pushed to the limits of the normal range of motion. As Yanai et al. postulated in 2000, impingement is likely caused by forcible elevation of the humeral head due to hyperextension upon the hand entering the water (cited in Heinlein & Cosgarea, 2010).

When swimmers are affected by impingement syndrome, there are several key alterations in their swimming strokes. First, during the gliding phase, the hand enters the water more lateral to the midline of the body, the humerus lower, and the elbow dropped (Heinlein & Cosgarea, 2010). These initial changes in the stroke alter the subsequent phases as well, and they coincide with alterations in the muscle activities. The gliding phase is marked by a decrease in anterior and middle deltoid, upper trapezius, and rhomboid activity while the pull-through phase displays significantly less serratus anterior activity combined with increased rhomboid activity (Heinlein & Cosgarea, 2010). As a result, there is a decrease in scapular upward rotation and protraction (Heinlein & Cosgarea, 2010). Next, during late pull-through and recovery, there is significantly less internal rotation since the hand exits the water earlier when the rhomboid activity increases to retract and elevate the scapula

(Heinlein & Cosgarea, 2010). Lastly, during the recovery phase, forward flexion is decreased due to decreased anterior deltoid activity, which causes the lateral hand entry upon the start of the next gliding phase (Heinlein & Cosgarea, 2010).

Though kinematic alterations are significant and measurable between impinged and non-impinged shoulders during head-down freestyle, there is debate over the genesis of the impingement. It is unclear whether these alterations are caused by existing impingement or if impingement is brought about by these changes (Heinlein & Cosgarea, 2010).

Mechanisms of Impingement Development in Head-Down Freestyle

Causes of impingement known to be multifactorial in swimming (Krüger, Michaud, & Stüwer, 2010). Unfortunately, many complications have heretofore prevented a consensus on the exact mechanisms of developing shoulder impingement. These include the fact that shoulder injuries are often developed concurrently, meaning that impingement is rarely an isolated condition; the multitude of anatomic, biomechanical and neuromuscular afflictions that can contribute to the development of or be worsened by impingement; and the cyclic nature of the development of impingement, i.e. factors that may contribute to the initial development, such as instability, are further aggravated by the impingement. Moreover, longitudinal studies have not been conducted, meaning that the exact mechanisms of injury in swimming are not clearly or definitively defined.

Multiple musculoskeletal factors are known to cause the development of impingement. Most documented are posterior capsule tightness, rotator cuff muscle imbalance, scapular dyskinesis, and scapulothoracic muscle dysbalance (Cools et al., 2007 & McKim, 1998, cited in Krüger et al., 2010). These, as well as other factors, are all seen in swimmers with impingement.

The mid-pull through and recovery phases of head-down freestyle are most likely to contribute to the instance of impingement since these phases require the arm to be within the “painful arc of abduction,” which occurs between -10 and 40 degrees of elevation (Yanai & Hay, 2000). In addition, the initial catch at the transition between glide and early pull-through phases as well as mid-pull through put the shoulder at risk

of impingement. Swimmers are capable, however, of altering their stroke technique to small degrees that can either induce, reduce, or prevent impingement (Yanai & Hay, 2000).

The initial catch phase can cause impingement since the arm is at high elevation and the resistive forces of the water on the long moment-arm of the fully extended arm can cause compressive forces on subacromial structures (Yanai & Hay, 2000).

During the pull-through phase, impingement can be caused due to the adduction and internal rotation of the shoulder (Yanai & Hay, 2000). Several alterations during this phase can also cause a higher likelihood of impingement. Specifically, the swimmer may drop the elbow, which creates a large amount of external rotation and horizontal adduction compared to the large internal rotation and horizontal abduction of the high-elbow condition (Yanai & Hay, 2000). The latter can contribute to impingement due to higher compressive forces in this position.

Finally, the recovery phase is most causative of impingement since it involves high amounts of shoulder abduction and external rotation (Yanai & Hay, 2000).

These rates of impingement within specific stroke phases are likely large contributors to the overall large number of instances of shoulder impingement among swimmers, but they are not the only factors that can contribute to such injury. Namely, speed, breathing motions, and practice techniques such as hand paddles and specific exaggerated stroke alteration drills can contribute although these have not been adequately studied at the present time.

Head-Up Freestyle Kinematics

Although there is currently there is a lack of empirical data on head-up freestyle, several discrete alterations from head-down freestyle that can be defined qualitatively. Most distinctly, the head and chest are elevated in head-up freestyle. The head stays pointing forward to see the field of play, and the wake that the chest creates is used to propel the ball forward during dribble swim. Strokes are altered in that they are much shorter and faster with the arm not passing the hips upon late pull-through/recovery, and the elbows are raised. The arms are also held wider to create stability. Figure 17 shows a comparison between head-down freestyle to head-up freestyle.

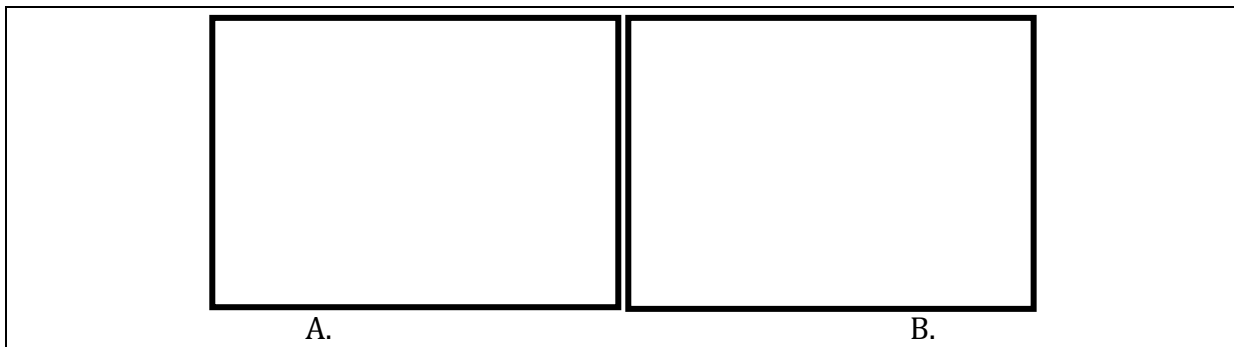


Figure 17: A. Traditional head-down freestyle swimmers keep their heads and chests in the water at all times while incorporating a large amount of lateral body roll. This style of freestyle is optimized for speed B. Water polo players perform freestyle stroke with their heads and chests erect out of the water in order to dribble the ball and to visualize the field of play. This style of swimming alters the stresses that affect the shoulders.

(Images from: <http://livehealthy.chron.com/swim-freestyle-getting-tired-3018.html>; <http://smithieinsports.wordpress.com/about/>)

Research Proposal

Title: Biomechanical Analysis of Head-Up Freestyle and Shoulder Impingement

Significance of Proposed Research:

Shoulder impingement syndrome is known to affect water polo players, but little research has been conducted relative to that of other sports. Water polo differs from all other throwing sports in that the kinematic sequence of the throwing technique inherently cannot rely on forces from contact with the ground. In addition, water polo players' shoulders are not only subject to stresses from repetitive throwing, but to continuous swimming and, to a smaller degree, continuous sculling as well. Moreover, with water polo being a contact sport, players are always at risk for acute shoulder traumas. In this way, water polo players' shoulders are subject to a broader range of stresses than most other sports in which there are only one or two major shoulder stressors. It is no surprise, therefore, that shoulder pain is the most common complaint among water polo players with impingement representing a large portion of such complaints.

Though it is logical reasoning to assume that the overhead throwing, swimming, and sculling aspects of water polo all contribute to and are affected by shoulder impingement, it is not clear how they relate. Specifically, the degree to which throwing, swimming, and sculling each contribute to the pathogenesis of impingement is not known, nor is the affect that impingement has on each of these skills. Such interactions require a great deal of study in order to fully understand the pathogenesis, perpetuation, complications, and effective treatments for impingement. Ultimately, the goal of such shoulder studies is to improve the health of athletes and to prevent injuries

from occurring. The first step in reaching this ultimate goal is to fundamentally understand the movements themselves by analyzing the normal kinematics and biomechanics of these actions, and subsequently compare these with those in impinged shoulders.

Freestyle, which is relatively well studied, is the major locomotory style in water polo. However, water polo freestyle is fundamentally different from the traditional stroke used in swimming competition in that the head and chest are brought above the water during water polo. With this alteration, the entire stroke is changed significantly: the elbows are brought higher, strokes are shorter and faster, lumbar lordosis increases, kick speed increases, and the body roll present in competitive swimming is nearly completely absent (Colville & Markman, 1999). So far, little research has been conducted on how these alterations affect shoulder movement and impingement in water polo players. The proposed research would be conducted in two parts to first establish the normal biomechanics of head-up swimming, and to then identify differences, if any, between head-up swimming performed with healthy and impinged shoulders. The information garnered from this study will act as a first step to improve rehabilitation and prevention techniques for water polo players with shoulder impingement.

Methods:

Participants:

This research would require the participation of expert water polo players, both with healthy shoulders and those with previously diagnosed shoulder impingement.

Participants must have a minimum of 5 years of current continuous competitive experience and must currently play at the collegiate level (Division I, II, or III). This study will be approved by the Scripps College IRB committee, and participants will be required to submit a questionnaire as well as sign an informed consent form (see appendix). Individuals that meet the requirements based on the questionnaire and above criteria will be examined for indications of shoulder impingement using Neer's impingement sign and Hawkin's test in order to control for any possible mis-diagnoses previous to this study. Any participant found to have any shoulder abnormalities apart from impingement will be dismissed from this study. Likewise, participants with any abnormality that prevents the individual from performing head-up swimming without severe pain and/or risk of further injury will be dismissed. Eligible participants will be split into two groups: Group 1 will be those with healthy shoulders while Group 2 will be those with prior impingement. Each group will require at least 30 participants each in order to achieve significant results.

Materials and Data Collection:

Each participant will be evaluated both on land and in the water. On land, participants' shoulders will be evaluated with impingent tests, as aforementioned, and split into groups. These groups will have no relevance to the participants themselves; they solely refer to the data set in which the results will be analyzed.

Data acquisition in the water will require electromyography and cinematic analysis in accordance with procedures described by Pink et al., Montgomery et al., and Townsend et al. (1991;1994;1991). All participants of both groups will perform head-up freestyle in a pool equipped with underwater windows while remaining stationary

with the use of an elastic band attached between the participant's waist and a diving block on the pool deck. Cinematographic data will be gathered using two high-speed cameras on the lateral side of the participant: one through an underwater window and one on the pool deck.

Electromyographic results will be obtained using fine-wire electrodes in accordance with the procedures described in the literature (Montgomery et al., 1994; Pink et al., 1991; Townsend et al., 1991). The muscles to be analyzed will be the anterior, middle, and posterior deltoids, serratus anterior, upper trapezius, rhomboid major, subscapularis, supraspinatus, infraspinatus, teres minor, latissimus dorsi, and pectoralis major. Dual 50-micron insulated wires with 2-3 mm bared tips will then be inserted into these muscles after skin preparation and muscle isolation using a 25-gauge hypodermic needle as a cannula, called the Basmajian single-needle technique (Montgomery et al., 1994; Townsend et al., 1991). Once inserted, insulated leads will be attached to the wires and waterproof dressings will be applied to insertion points. Leads from each wire will be attached to a ground plate, which will be placed inside a plastic waterproof container and secured to the participants' waists such that the buoyant container floats beyond the subject so as to leave the swim stroke uninhibited. Signals from the electrodes will be transmitted via battery powered FM-FM telemetry system are recorded with a Model 42000-A Bio-Sentry Telemetry device. This transmitting device will also be placed within the aforementioned plastic container. To insure correct placement of the electrodes, each muscle will be electrically stimulated individually on land and displayed on an oscilloscope. Once subjects are properly fitted

with electrodes, baseline muscle activity will be recorded with subject passively floating in order to normalize the data.

Each participant from both Group 1 and Group 2 will swim head-up for two minutes in either direction to control for discrepancies between the left and right shoulders. Starting direction will be random to control for altered results due to fatigue. EMG data will be monitored remotely on an oscilloscope and recorded for later review. This data will be synchronized with cinematographic data by placing an electronic marker on the film and EMG data. EMG and cinematographic data will be analyzed by computer integration of signals.

Statistical Analysis:

Results will be statistically analyzed using independent t-tests with an alpha level of 0.05. The data obtained in Part I will be statistically analyzed in comparison to electromyographic and cinematographic data of normal head-down swimming in the literature (Pink et al., 1991). The Part II data will be statistically analyzed in comparison the electromyographic and cinematographic data obtained in Part I.

Confounding Variables:

It is possible that elastic band will alter normal biomechanics since participants must adapt to an external drag force acting on the trunk rather than compensating for normal drag force to progress forward. However, since cinematographic analysis would be increasingly difficult with a moving subject, this risk is unavoidable. In addition, since every participant will be evaluated in the same conditions and the statistical

analyses will look at the differences between them, it is hopeful that the differences would be of the same order of magnitude as if tests were done under normal swimming conditions.

Conclusions:

The results of this study could potentially unveil clues to the pathogenesis of shoulder impingement in water polo players. Muscle activation in head-up swimming will almost undoubtedly be significantly different, both in sequence and in strength of contraction. In addition, it is extremely likely that body position will be significantly different between head-up and head-down freestyle, and it is a distinct possibility that body position will also be significantly different between healthy and impinged shoulders during head-up freestyle. With a comparison to traditional head-down freestyle, it is possible that similar muscle alteration patterns occur with impinged shoulders in head-up freestyle. Alternatively, there could be a wholly different pattern that could provide the basis for understanding of water polo-specific shoulder injuries.

Based on studies of head-down freestyle, several hypotheses as to how head-up freestyle and impingement relate can be made. First, since the lateral body roll in head-down swimming is theorized to allow for more clearance of the humeral head beneath the acromion during the glide, catch, and beginning pull-through phases of the stroke by way of increased scapular rotation, it is likely that the lack of body roll in head-up swimming will put the athlete at a greater risk of impingement since there will likely be less clearance of the humeral head. Secondly, as described by Yanai and Hay, high elbows in head-down freestyle provide a mechanical advantage relative to dropped

elbows, but put the shoulder at a greater risk of impingement since there is increased internal rotation and horizontal abduction (2000). Since head-up freestyle requires exaggeratedly high elbows, it follows that this may put shoulders at a greater risk of impingement than head-down. Collectively, the lack of body roll and high elbow components contribute to the hypothesis that head-up freestyle has a higher risk of shoulder impingement than does head-down. Alternatively, long strokes such as those utilized in head-down freestyle create a long moment arm, which contributes to a compressive force on the internal structures of the shoulder, which in turn provides a risk of impingement (Yanai & Hay, 2000). In this way, the shorter strokes in head-up freestyle could relieve this compressive force since there will be a shorter moment arm. The results of the proposed study are expected to shed light on the validity of these hypotheses.

This study could increase the safety of water polo players both by providing the first step to determining whether the method of optimal head-up technique should be modified or whether the current technique is the safest possibility of the shoulder if performed correctly and with the aid of preventative measures such as targeted exercises and stretching. In the case of the latter, this study could lead to discovering which specific muscles need to be strengthened in order to prevent impingement and/or treat impingement. Ultimately, the goal for this study is to provide a foundation towards making water polo safer for the athletes without compromising performance.

Further studies should include investigations of the affect of fatigue and poor technique on the rate of impingement development, comparisons of the patterns of biomechanical alterations in impinged and healthy shoulders between head-up and

head-down freestyle, and analyses of the risk of impingement during each phase in the head-up swim stroke.

Appendix: IRB Materials

Item 1: Application for IRB Cover Sheet

Application for Institutional Review Board Review

Please submit this form with a Research Summary and supporting materials following the guidelines given below. The investigator should allow sufficient time for review before scheduling the implementation of the project. If the proposal requires the approval of the full committee, it could be a month before a decision is made.

Principal Investigator:
Address Line 1:
Address Line 2:
Telephone:
E-Mail:
Department:
Title of Project:

The principal investigator assures the IRB that all procedures carried out under the project will be conducted by persons legally and responsibly entitled to do so, and that any deviation from the submitted project (change in principal investigator, participant recruitment procedures, research methodology, etc.) will be submitted to the IRB for approval prior to implementation.

The IRB also requires that the principle investigator and faculty sponsor read the Belmont Report and take the Web training course for IRB members provided by the [Office of Human Subjects Research, NIH](#). For OHRP training, [click here](#).

Please indicate your compliance:

I have read the Belmont Report. Attached is a "Completion Certificate" for the IRB Members' training session.

Please indicate whether or not the following are involved.

Project uses federal funding:	<input type="checkbox"/> Yes	<input checked="" type="checkbox"/> No
Patients as participants:	<input type="checkbox"/> Yes	<input checked="" type="checkbox"/> No
Minors as participants (under 18):	<input type="checkbox"/> Yes	<input checked="" type="checkbox"/> No
Elderly participants (over 65):	<input type="checkbox"/> Yes	<input checked="" type="checkbox"/> No
Non-English-speaking participants:	<input type="checkbox"/> Yes	<input checked="" type="checkbox"/> No
Cognitively impaired participants:	<input type="checkbox"/> Yes	<input checked="" type="checkbox"/> No
Prisoners or parolees:	<input type="checkbox"/> Yes	<input checked="" type="checkbox"/> No
Participants in other countries:	<input type="checkbox"/> Yes	<input checked="" type="checkbox"/> No
Greater than minimal risk* to participants:	<input type="checkbox"/> Yes	<input checked="" type="checkbox"/> No
Film-, video-, or voice-recording of participants:	<input checked="" type="checkbox"/> Yes	<input type="checkbox"/> No
Yes/No questionnaires:	<input checked="" type="checkbox"/> Yes	<input type="checkbox"/> No

Data banks, archives, or medical records: Yes No
Payment for participants: Yes No
Interviews: Yes No
The use of drugs or medication: Yes No
Taking physical specimens: Yes No
Deception: Yes No
Principal investigator (signature): Kelly Doring
Date: 12/9/2013
Faculty Sponsor (print): Dr. John Milton
Faculty Sponsor (sign): _____
Date: _____
Department: Biology

Review Board Action

1. Certified as exempt from review (by Chair)
2. Approved under expedited review (by Chair or other IRB member)
3. Approved by full committee
4. Returned by full committee for additional details, clarifications, or adjustments

IRB Representative (signature): _____
Date: _____

Item 2: Research Summary

Title of Research: Biomechanical Analysis of Head-Up Freestyle and Shoulder Impingement

Principal Investigator: Kelly Davis

Research Questions: What is the kinematic sequence of the head-up freestyle stroke and what muscles are active during each phase of the cycle? How does this kinematic sequence compare to that of traditional head-down freestyle in the literature? How is the kinematic sequence and muscle activation altered in subjects with impinged shoulders?

Participants:

Nature of Participants: Expert water polo field players (at least 5 years prior experience and current participation in collegiate-level water polo) with either normal shoulders or previous shoulder impingement.

Recruitment: Advertisements, approved by NCAA and SCIAC, will be distributed at SCIAC water polo games as well as in local newspapers and Facebook. Interested players will call or email the principle investigator, and they will be sent a brief questionnaire (below) to fill out and send back to the principle investigator. Players that meet the prerequisites of the study based on the questionnaire will be informed and asked to come to the pool during a pre-designated time. All participants need not be present at the same time. Participants will be given an informed consent form and evaluated for shoulder impingement using manual tests. Participants with shoulder maladies other than impingement will be dismissed. Likewise, participants with impingement severe enough prevent the individual from swimming head-up freestyle without severe pain and/or risk further injury will be dismissed. Participants will not be personally identified in this study.

Consent: As aforementioned, participants will be required to sign an informed consent from (below) in order to participate in this study.

Methods: Before swimming, participants' shoulders will be evaluated with range of motion and impingement tests. Participants will be divided into two groups based on the results of these tests: Group 1 with healthy shoulders and Group 2 with impinged shoulders.

Part I: High-speed cameras will be positioned both on the pool deck and through below-surface windows of the pool. These will be set up such that they capture the subjects' motion from a lateral view. Fine-wire electrodes will be inserted into the shoulders of Group 1 participants, which will be secured with waterproof dressings. Wires will be secured in such a way that they do not affect the stroke of the participants, then gathered in a small plastic container attached to the subjects' waists, which will also house the signal amplifier. Each participant will be remotely secured to a diving block on the pool deck using a standard elastic cord attached to the participant's waist, which will prevent forward progression of the subject while providing minimal interference with the swim stroke. Participants will swim head-up freestyle for two-minute intervals while being recorded by the high-speed cameras and electrodes.

Part II: The same procedure as described above will be conducted with Group 2 participants.

Benefits: This study will provide a basis of knowledge for how head-up freestyle contributes to shoulder impingement among water polo players. Part I will establish the biomechanical basis for how the stroke is performed in relation to muscle activation, body positioning, and timing of stroke phases as compared to traditional head-down freestyle. Part II will determine differences in muscle activation, body positioning and timing of stroke between healthy and impinged shoulders during head-up freestyle. This knowledge is an essential first step to understanding mechanisms of impingement among water polo players since there is a range of possible causes within the sport. As of yet, there is a lack of understanding of head-up freestyle such that preventative and rehabilitative measures are not optimally effective. Ultimately, this study will provide a foundation for improving player safety.

Risks to Participants: Participants will be subject to minimal risks, though there will be some. Head-up freestyle poses a risk of shoulder injuries; however, since little is known about head-up freestyle, we cannot adequately estimate the severity of this risk. In addition, fine-wire electrodes present a risk since they are inserted directly into the muscle. These electrodes are generally very safe but there is nevertheless risk of minor injuries due to misplacement or incorrect movements and a small risk of infection.

To mitigate these risks, precautions will be taken. Participants will swim for no more than two minutes at a time to prevent any possible injury due to fatigue or overuse. A high level of care and precaution will be used to place the electrodes as well as to waterproof them, and this will be done in accordance with protocols set forth in the literature. In addition, a lifeguard will be present on the pool deck at all times.

Questionnaire:

- Are you currently playing for a NCAA collegiate team at Division I, II, or III? Please specify.
- What is your current age?
- How many consecutive years have you played competitive water polo in the field (excluding goal keeper experience)?
- Have you ever stopped playing for a season or more? Due to injury?
- Have you ever had shoulder pain while playing water polo in the last 5 years? Please elaborate.
- Have you ever been diagnosed with a shoulder injury in the past 5 years? Please explain.
- Have you been diagnosed with shoulder impingement in the last 5 years?
- Have you ever had shoulder surgery? Please explain.
- Do you have any existing injuries that prevent you from swimming head-up without considerable pain? Please explain.

Item 3: Informed Consent Form



Informed Consent Form

[This Informed Consent Form for collegiate water polo players who we are inviting to participate in research on shoulder injuries in head-up freestyle. The title of our research is “Biomechanical Analysis of Head-Up Freestyle and Shoulder Impingement”]

Principle Investigator: Kelly Davis

Organization: Keck Science Department of the Claremont Colleges and CMS Athletics

Proposal: Biomechanical Analysis of Head-Up Freestyle and Shoulder Impingement

This Informed Consent Form has two parts:

- **Information Sheet (to share information about the research with you)**
- **Certificate of Consent (for signatures if you agree to take part)**

You will be given a copy of the full Informed Consent Form

PART I: Information Sheet

Introduction

I am an undergraduate student of Scripps College, researching for Keck Science Department. We are investigating the biomechanics of head-up freestyle in water polo and how it is affected by shoulder impingement. You are invited to participate in this study if you so choose. As a part of this research, you will be asked swim head-up freestyle while being recorded by high-speed cameras and fine-wire electrodes. This research will provide a basis for increasing the safety of water polo players. If you so choose, you can talk to the principal investigator before deciding whether or not you will participate in the research to discuss any concerns or questions you may have regarding the study.

Purpose of the research

Traditional head-down freestyle has been relatively well researched in relation to shoulder impingement. Most of the research that has been conducted on water polo has been focused on the throwing aspect rather than the head-up freestyle stroke. Therefore, little information about head-up freestyle in relation to shoulders is known. This study aims to create a foundation of knowledge of the head-up stroke and its relationship with shoulder

impingement by understanding the exact body position, sequence of movement, and muscle activations of the shoulders during the stroke. Then, we will investigate the stroke alterations in subjects with impinged shoulders in order to begin to understand how shoulder impingement is related to head-up freestyle. Ultimately, the goal in this research is to establish a foundation to understand how to improve player safety.

Type of Research Intervention

The research will involve a few preliminary steps in which the participants will be evaluated for shoulder injuries and shoulder mobility using manual tests. Then, after participants are fitted with specialized fine-wire electrodes that will be inserted directly into shoulder muscles, they will perform head-up freestyle in a pool for a short amount of time while being recorded by two high-speed cameras.

Participant selection

You have been selected for this study since you are an active collegiate water polo field player and either have normal shoulders or shoulders with previous impingement. We require that all participants have 5 or more years of continuous competitive experience prior to this study and are at least 18 years of age.

Voluntary Participation

Your participation in this study is entirely voluntary. You may choose whether to participate or not. If you choose to not participate, there will be no repercussions from the research team.

Procedures and Protocol

You will only be required to come to the testing site once for a few hours. The following is a description of what to expect upon your visit:

- Your shoulders will be evaluated with physical diagnostic examinations used by physical therapists and athletic trainers. These evaluations are non-invasive and will cause only minimal pain if an injury is present.
- You will then be fitted with fine-wire electrodes using a 27-gauge hypodermic needle (about 0.0165 inches in diameter). These are very thin wires, about 5 microns in diameter (fractionally larger than the diameter of a human hair). They are not painful and should not inhibit movement. You will have no more than 12 in one shoulder. The wires will be gathered and placed inside a waterproof plastic container that will contain a transmitting device and will be attached to your waist. Waterproof dressings will be applied to all insertion points.
- On land, you will relax your muscles while baseline data confirms correct electrode placement.
- You will be asked to enter the pool with electrodes attached, and you will be instructed to attach one end of an elastic cord to your waist via a Velcro strap. The other end will be secured to a diving block on the pool deck.
- You will be asked to float on your back while baseline data is recorded through your electrodes before you swim.
- You will be asked to perform head-up freestyle at a moderate to fast pace twice for two minutes each. The elastic cord will keep you stationary, and

high-speed cameras will record you from the side of the pool and from an underwater window. Between each swim, you will be instructed to rest to prevent muscle fatigue.

- After your swims, you will remove your elastic cord, exit the pool and the electrodes will be carefully removed.

Risks

The risks involved in this study include minor pain from electrode placement and potential shifting of electrodes. Very occasionally, infection can occur at the site of electrode placement.

Benefits

This study will provide the basis of knowledge for how head-up freestyle contributes to shoulder impingement among water polo players. It will establish the biomechanical basis for how the stroke is performed in relation to muscle activation, body positioning, and timing of stroke phases as compared to traditional head-down freestyle. In addition, it will determine differences in muscle activation, body positioning and timing of stroke between healthy and impinged shoulders during head-up freestyle. This knowledge is an essential first step to understanding mechanisms of impingement among water polo players since there is a range of possible causes within the sport. As of yet, there is a lack of understanding of head-up freestyle such that preventative and rehabilitative measures are not optimally effective. Ultimately, this study will provide a foundation for improving player safety

Confidentiality

Any information you provide will be kept completely confidential and will only be used to in data analysis within this particular study. Only researchers directly involved in this study will have any access to the information you provide. No personal information will be used in publications.

Right to Refuse or Withdraw

You do not have to take part in this research if you do not wish to do so, and you may withdraw at any time with no repercussions. It is your choice and all of your rights will be respected.

Who to Contact

If you have any questions or concerns relative to this study, please contact the principal investigator:

Kelly Davis
1030 Columbia Ave
Claremont, Ca 91711
(408) 497-6260

This proposal has been reviewed and approved by the Scripps College IRB committee, which is a committee whose task it is to make sure that research participants are protected from harm.

PART II: Certificate of Consent

I have read the foregoing information, or it has been read to me. I have had the opportunity to ask questions about it and any questions that I have asked have been answered to my satisfaction. I consent voluntarily to participate as a participant in this research.

Print Name of Participant _____

Signature of Participant _____

Date _____
Day/month/year

If illiterate

A literate witness must sign (if possible, this person should be selected by the participant and should have no connection to the research team). Participants who are illiterate should include their thumb-print as well.

I have witnessed the accurate reading of the consent form to the potential participant, and the individual has had the opportunity to ask questions. I confirm that the individual has given consent freely.

Print name of witness _____

AND Thumb print of participant

Signature of witness _____

Date _____
Day/month/year



Statement by the researcher/person taking consent

I have accurately read out the information sheet to the potential participant, and to the best of my ability made sure that the participant understands that the following will be done:

- 1.**
- 2.**
- 3.**

I confirm that the participant was given an opportunity to ask questions about the study, and all the questions asked by the participant have been answered correctly and to the best of my ability. I confirm that the individual has not been coerced into giving consent, and the consent has been given freely and voluntarily.

A copy of this ICF has been provided to the participant.

Print Name of Researcher/person taking the consent _____

Signature of Researcher /person taking the consent _____

Date _____
Day/month/year

Acknowledgements

I would like to thank all of the people who made this project possible. Firstly, I am indebted to Steve Graves ATC for taking me on, giving me advice, and supplying me with ample resources. In addition, I would like to thank Dr. Milton for helping me with my poster, providing books and articles, and giving me direction on top of his immense workload. Lastly, I am grateful for the helpful advice all of my peers and teammates have given me throughout the process.

Works Cited

- Behnke, R. S. (2006). *Kinetic Anatomy*. Champaign, IL: Human Kinetics.
- Browne, A., Pink, M., Jobe, F. W., & Kerrigan, J. (1988). Painful Shoulder During Freestyle Swimming: Cinematographic Analysis of Twelve Muscles. *The American Journal of Sports Medicine*, 19(6).
- Colville, J. M., & Markman, B. S. (1999). Competitive Water Polo: Upper Extremity Injuries. *Aquatic Sports and Rehabilitation*, 18(2), 305–312.
- Drakos, M. C., Rudzki, J. R., Allen, A. a, Potter, H. G., & Altchek, D. W. (2009). Internal impingement of the shoulder in the overhead athlete. *The Journal of bone and joint surgery. American volume*, 91(11), 2719–28. doi:10.2106/JBJS.I.00409
- Franić, M., Ivković, A., & Rudić, R. (2007). Injuries in water polo. *Croatian medical journal*, 48(3), 281–8. Retrieved from <http://www.ncbi.nlm.nih.gov/pubmed/22107072>
- Gray, H. (1977). *Gray's Anatomy: The Classic Collector's Edition*. (T. P. Pick & R. Howden, Eds.). New York, NY: Bounty Books.
- Heinlein, S. a, & Cosgarea, A. J. (2010). Biomechanical Considerations in the Competitive Swimmer's Shoulder. *Sports health*, 2(6), 519–25. doi:10.1177/1941738110377611
- Kibler, W. Ben. (1998). Current Concepts The Role of the Scapula in Athletic Shoulder Function, 26(2).
- Krüger, K., Michaud, M., & Stüwer, K. (2010). *Subacromial Impingement in Competitive Swimmers*. European School of Physiotherapy.
- Kurz, T. (2003). *Stretching Scientifically: A Guide to Flexibility Training*. Island Pond, VT: Stadion. Retrieved from http://web.mit.edu/tkd/stretch/stretching_8.html#SEC90
- Levy, A. M., & Fuerst, M. (1993). *Sports Injury Handbook: Professional Advice for Amateur Athletes*. New York, NY: John Wiley.
- Meister, K. (2000). Current Concepts Injuries to the Shoulder in the Throwing Athlete Part One : Biomechanics / Pathophysiology / Classification of Injury. *The American Journal of Sports Medicine*, 28(2), 265–275.
- Montgomery, W. H., Pink, M., & Perry, J. (1994). Electromyographic Analysis of Hip and Knee Musculature During Running. *The American Journal of Sports Medicine*, 22(2), 272–278. doi:10.1177/036354659402200220
- Neer, C. S. (1983). Impingement lesions. *Clinical orthopaedics and related research*, 70–77. doi:10.1097/00003086-198303000-00010
- Pink, M., Perry, J., Browne, A., Scovazzo, M. L., & Kerrigan, J. (1991). The Normal Shoulder During Freestyle Swimming. *American Journal of Sports Medicine*, 19(6), 569–576.
- Saulsbery, C. M., & Hollister, A. (n.d.). Shoulder Impingement. *LSU Health Sciences Center*. LSU Health Sciences Center. Retrieved from <http://lib.sh.lsuhs.edu/portals/orthopaedic/shoulderimpingement.pdf>
- Tagliafico, A. (2012). *A Radiologically-Guided Approach to Musculoskeletal Anatomy*. Springer.
- Townsend, H., Jobe, F. W., Pink, M., & Perry, J. (1991). Electromyographic analysis of the glenohumeral muscles during a baseball rehabilitation program. *The American journal of sports medicine*, 19(3), 264–72. Retrieved from <http://www.ncbi.nlm.nih.gov/pubmed/1867334>

- Van De Graaff, K. M. (2002). *Human Anatomy*. (M. J. Lange & K. A. Queck, Eds.) (Sixth.). New York, NY: McGraw-Hill.
- Witwer, A., & Sauers, E. (2006). Clinical Measurements of Shoulder Mobility in College Water-Polo Players. *Journal of Sport Rehabilitation*, 15(1), 45–57.
- Yanai, T., & Hay, J. G. (2000). Shoulder Impingement in Front-Crawl Swimming: II. Analysis of Stroking Technique. *Medicine & Science in Sports & Exercise*, (April 1998).